



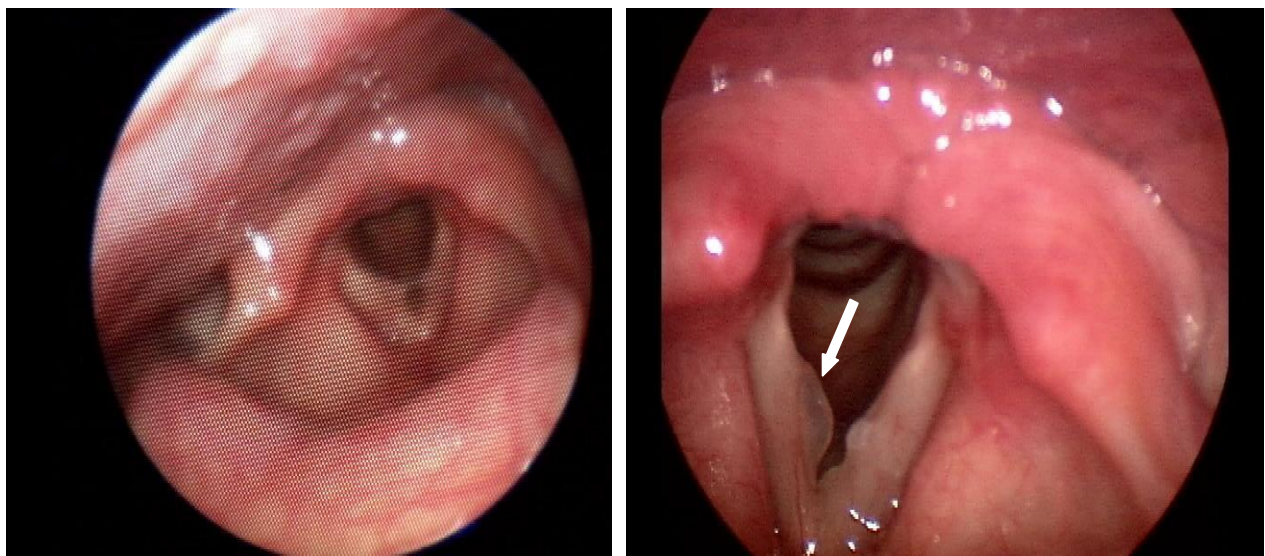
Vocal Fold Nodules (“Nodes”)

It is not uncommon to have patients come to the Voice Center, having been told they have “nodes.” The correct term for these lesions is vocal fold nodules and as a matter of fact, these are not nearly as common as you might think.

Very often, the low-resolution pictures that a general otolaryngologist is able to obtain make diagnosis of your vocal problem difficult. Without the right training and expertise, all bumps on the vocal folds are called nodules and a patient walks away with the wrong diagnosis. This may lead to incorrect treatment plans and worsening of the problem.

At the Voice Center, our specially trained physicians examine your vocal folds under a much higher magnification and with a highly-specialized technology called *videostroboscopy*. This exam is centered around your voice, and evaluating the true nature of your problem. All too often, we see patients who have been suffering for years under a misdiagnosis that was based on poorer technology and visualization.

An example of this is seen below:



You can see how the bumps are barely visible when viewed through the flexible laryngoscope (left), which is the scope that most general otolaryngologists use. However, when the same exact patient is correctly assessed with videostroboscopy (right), the true nature of the masses (polyps) become clear even to an untrained eye. The treatments for these two lesions are completely different.

The most important thing before pursuing treatment for your vocal fold nodules is to make sure that you have the right diagnosis. Once you have confirmed this, luckily, these lesions frequently respond to non-surgical treatment.